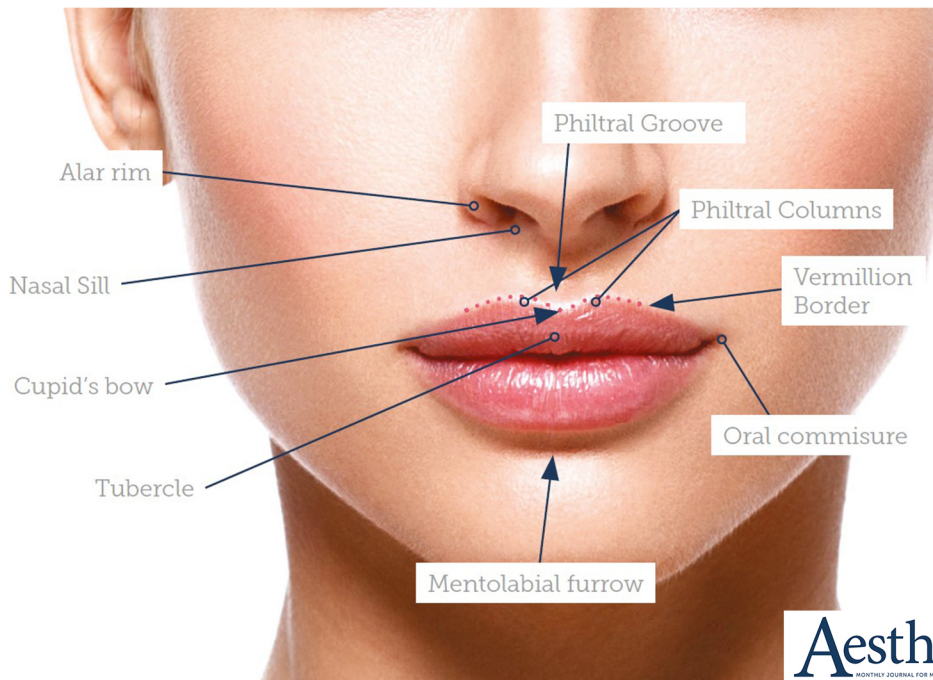


Anatomy of soft tissue in perioral area

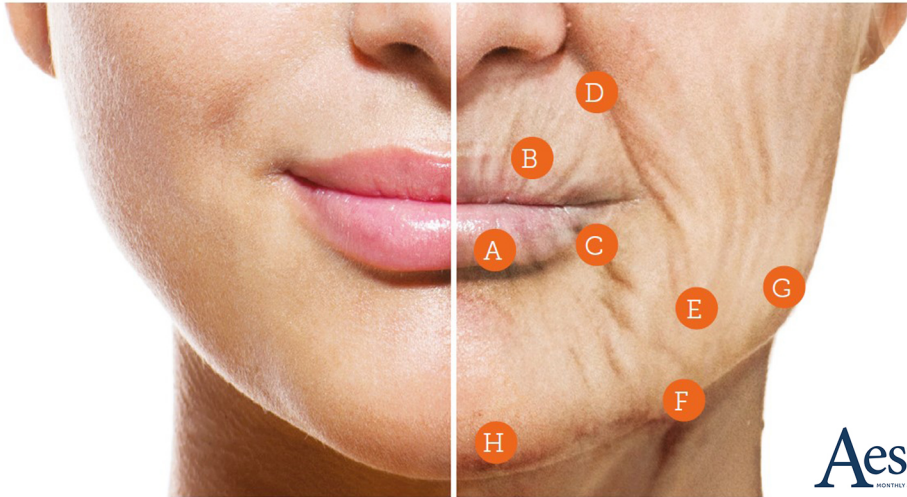


Aesthetics
MONTHLY JOURNAL FOR MEDICAL AESTHETIC PROFESSIONALS

Full article

Devlin M and Downie J, *Aesthetics Journal*, Treating the Cupid's Bow, January 2019 < <https://aestheticsjournal.com/feature/treating-the-cupid-s-bow> >

The Areas Within the Perioral, Jawline and the Chin in the Lower Face



Aesthetics
MONTHLY JOURNAL FOR MEDICAL AESTHETIC PROFESSIONALS

Perioral: lips (A), radial lip lines (B), oral commissure (C), nasolabial lines (D), marionette lines (E)

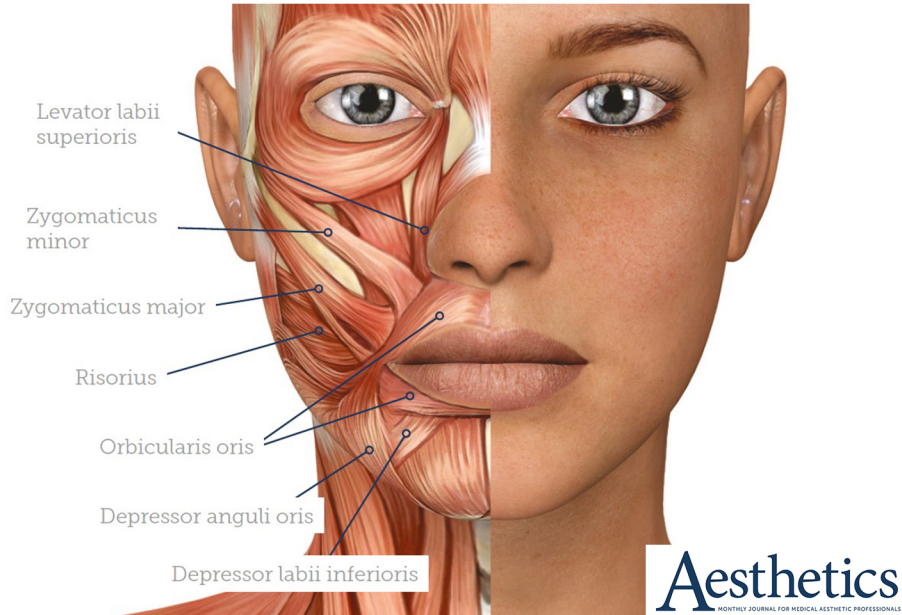
Jawline: mandibular loss of definition, which relates to masseters (G) the jowls (F)

Chin: mentalis (H)

Full article

Ullah Z, *Aesthetics journal*, Lower Face Aesthetics, June 2018 <<https://aestheticsjournal.com/feature/lower-face-aesthetics>>

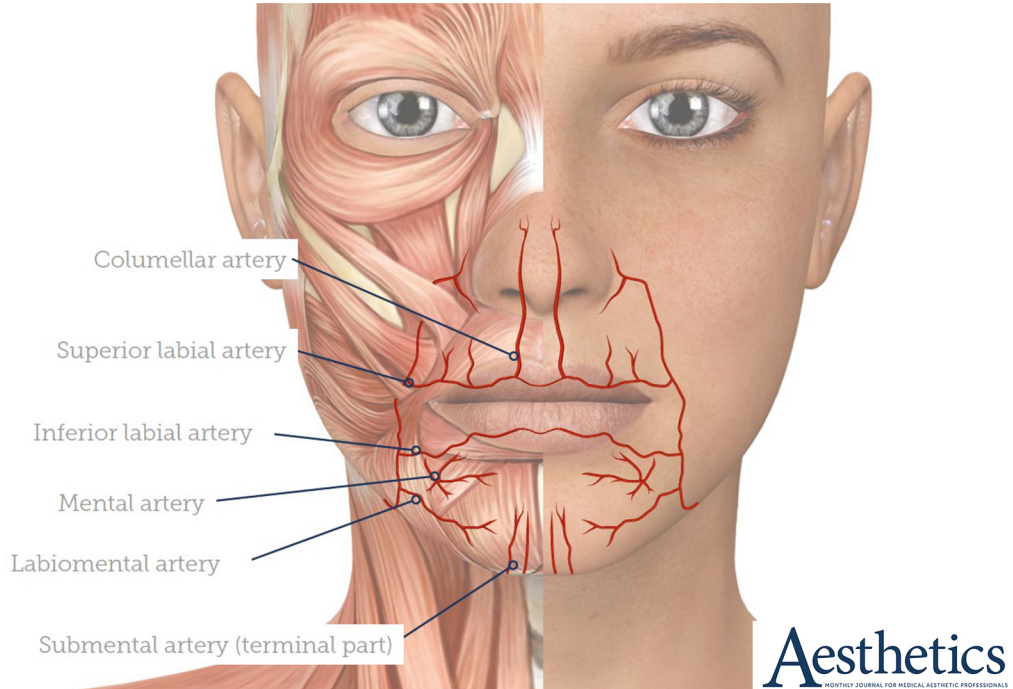
Where the Vessels Lie in Relation to the Muscle



Full article

Devlin M and Downie J, *Aesthetics journal*, Treating the Cupid's Bow, January 2019 < <https://aestheticsjournal.com/feature/treating-the-cupid-s-bow> >

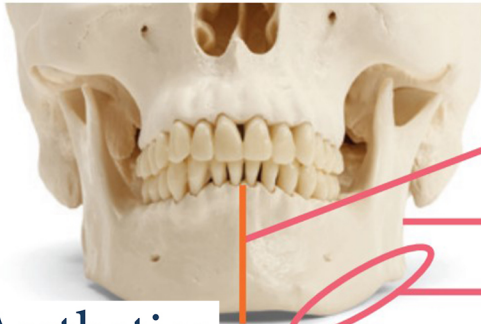
Where the Vessels Lie in Relation to the Muscle



Full article

Devlin M and Downie J, *Aesthetics journal*, Treating the Cupid's Bow, January 2019 < <https://aestheticsjournal.com/feature/treating-the-cupid-s-bow> >

Anatomical features of the mandible

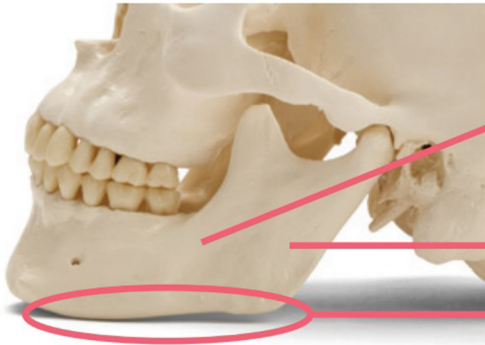


Mentonian
symphysis

Mandibular ramus

Mandibular line

Aesthetics
MONTHLY JOURNAL FOR MEDICAL AESTHETIC PROFESSIONALS



Mandibular body

Mandibular ramus

Mandibular line

Full article

Baker A, *Aesthetics journal*, Augmenting the Chin, November 2017
<<https://aestheticsjournal.com/cpd/module/augmenting-the-chin>>